



ISSN NO. 2320-5407

Journal homepage: <http://www.journalijar.com>

INTERNATIONAL JOURNAL
OF ADVANCED RESEARCH

RESEARCH ARTICLE

Effect of aqueous saffron extract (*Crocus sativus* L.) on sodium valporate-induced histological and histochemical alterations in liver of albino rats

Yosry A. Okdah¹, Seham A. Ibrahim^{2*}

1. Zoology Department, Faculty of Science, Menoufia University, Egypt

2. Zoology Department, Faculty of Science, Banha University, Egypt

Manuscript Info

Manuscript History:

Received: xxxxxxxx

Final Accepted: xxxxxxxxxxxxxxxx

Published Online: xxxxxxxxxxxxxxxx

Key words:

Sodiumvalporate, Saffron,
hepatotoxicity, Histochemistry

*Corresponding Author

Yosry A. Okdah

Abstract

The present study was aimed to assess the effect of aqueous saffron extract (*Crocus sativus* L.) on sodium valporate (SVP) hepatotoxicity in albino rats. Treating rats with SVP induced many histological changes in the liver including cytoplasmic vacuolization of the hepatocytes, fatty degeneration and congestion of blood vessels. Biochemical results showed an increase in serum ALT and SAT. Moreover, SVP caused a reduction in total carbohydrates, total proteins and DNA in the hepatocytes. Animals treated with SVP and aqueous saffron extract revealed an improvement in the histological, histochemical and liver function enzymes, ALT and AST induced by SVP. These results indicated that saffron extract improved hepatotoxicity of SVP through inhibition of oxidative stress and enhancing the antioxidant defense system.

Copy Right, IJAR, 2014., All rights reserved.

Introduction

Antiepileptic drugs are a diverse group of pharmaceuticals used in the treatment of epileptic seizures. Depakine, Sodium valproate, is an anticonvulsant used in the treatment of epilepsy, anorexia nervosa, panic attack, anxiety disorder, posttraumatic stress disorder, migraine, and bipolar disorder, as well as other psychiatric conditions requiring the administration of mood stabilizers (Gelder et al., 2006). On the other hand valproate was found to be associated with many side effects. Stephens and Levy (1992) reported that depakene can cause liver damage and cause pancreatitis which occasionally progress to bleeding and death. Janneke et al. (2010) found that there is significant associations between exposure of the unborn child to valproic acid monotherapy in the first trimester and Spina bifida, arterial septa defects, cleft palate, hypospadias, polydactyl and craniosynostosis. Aktas et al., (2010) reported that valproic acid caused degenerative changes in kidney of pregnant rats. Coyle et al., (2005) reported 3 cases of valproic acid related leukemia. Gokee et al., (2010) reported a valproic acid-associated vanishing bile duct syndrome in a 8- years old girl treated with valproic acid. Liver biopsy revealed portal inflammation, severe bile duct loss, and cholestasis. Valproic acid is also a teratogen; in utero exposures may result in the induction of neural tube defects, heart abnormalities, craniosynostosis, and skeletal malformations, such as ectrodactyly and syndactyly (Ornoy, 2006).

Crocus sativus L. commonly known as saffron, is a perennial stemless herb of the Iridaceae family and widely cultivated in Iran and other countries such as India and Greece. Iran accounts for approximately 90% of the world production of Saffron (Rios et al.1996). Saffron has along medicinal history as part of traditional healing, several modern research studies have hinted that the spice has possible anticarcinogenic, antimutagenic, immunomodulating and antioxidant like properties (Nair et al.1995). Saffron stigmas and petals, showed antidepressant effects. (Husseinzadeh et al., 2004). Nair et al., (1991) reported the anticancer activity of saffron extract (dimethyl crocetin) against a wide spectrum of murine tumors and human leukemia cell lines. Premkumar et al., (2003) studied the chemoprotective potential of saffron against the genotoxicity of three well- known anti-tumor drugs cisplatin, cyclophosphamide, and mitomycin using comet assay. Iranshahi et al. (2011) reported that aqueous and ethanolic

extracts of saffron exhibit hepatoprotective effects against liver damages induced by CCl_4 in mice. The present work designed to investigate the protective effect of saffron extract on sodium valporate-induced hepatotoxicity in albino rats.

Materials and methods

Adult male rats of Wistar strain, 140 ± 5 g, were housed in groups of two per cage, maintained under controlled conditions of temperature ($22 \pm 2^\circ\text{C}$) and light (12 :12 L : D) and provided with food and water ad libitum. They were acclimated for one week prior to the experiment. Animal experiments and housing procedures were performed in accordance to the animal care rules approved by the authorities of Menoufia University, Egypt. Animals were divided into 4 groups:

Group I: Animals of this group (10 rats) had been kept as controls and were given basal diet.

Group II: Animals of this group (10 rats) were administered by gavage saffron extract at a dose level of 20 mg/kg body weight, once/ week for 6 weeks.

Group III: Animals of this group (15 rats) were orally given sodium valporate (SVP) at a dose level of 25mg/kg body weight daily dissolved in water for 6 weeks. Sodium valproate was purchased from local pharmacy in the form of tablets with trade name Depakine (Sanofi Synthelabo, France), each containing 200 mg of sodium valproate.

Group IV: Animals of this group (25 rats) were orally given the same dose of SVP and saffron extract for 6 weeks.

Preparation of saffron extract

Saffron, the dried stigmas of *Crocus sativus* flower were obtained from Al-alawy market in Jeddah, Saudi Arabia. One gram of saffron was soaked in 100 ml distilled water. After 2 h it was homogenized in the same distilled water, stirred for 1 h and filtered. The residue was re-extracted with fresh distilled water. This aqueous extract was lyophilized and stored at 4°C until further use (Premkumar et al.2003).

Histological and histochemical examination

Animals of different groups were dissected out after 3 and 6 weeks and their livers were carefully separated and washed in normal saline. Specimens were fixed in alcoholic Bouin's fluid or Carnoy's fixative. Fixed materials were embedded in paraffin wax and sections of 5 micrometer thickness were cut. Slides were stained with haematoxylin and eosin for histological examination. For histochemical demonstration of total carbohydrates periodic acid Schiff's technique (PAS) (Kiernan, 1981) was used. Total proteins were detected using the mercury bromophenol blue method (Pearse, 1972) and DNA was detected using Feulgen reaction (Kiernan, 1981).

Biochemical assays

For enzymes determination, blood samples were collected from animals after 6 weeks of treatment. Sera were obtained by centrifugation of the blood sample and stored at -20°C until assayed for the biochemical parameters. Aspartate aminotransferase (AST) and alanine aminotransferase (ALT) were measured according to the method of Reitman and Frankel (1957).

Statistical Analysis

Data were expressed as mean values \pm SD and statistical analysis was performed using one way ANOVA to assess significant differences among treatment groups. The criterion for statistical significance was set at $P < 0.05$. All statistical analyses were performed using SPSS statistical version 16 software package (SPSS@ 4 Inc., USA).

Results

Histological results

Liver of control rats and rats given saffron extract showed normal histological structure (Fig.1a). Examination of liver of rats treated with SVP displayed many histopathological alterations. After three weeks from the beginning of the administration of SVP, the liver tissue revealed disruption of normal cords arrangements of the hepatocytes. The intrahepatic blood veins were congested (Fig.1b). Infiltrations by large mass of leucocytic inflammatory cells were observed (Fig.1c). The blood sinusoids could not be seen as they suffered from great narrowing. The hepatocytes showed cytoplasmic vacuolation and the nuclei were pyknotic (Fig.1d). These histopathological changes were more pronounced after 6 weeks where the liver showed bile duct proliferation (Fig.2a) and the hepatic cells were degenerated and appeared with fatty infiltrations (Fig.2b) and. Animals treated with saffron and SVP for 3 weeks revealed that few veins appeared congested and there were a few masses of leucocytic inflammatory cells. Examination of liver sections after 6 weeks revealed that liver tissue restored most of its normal structure and most cells displayed a certain degree of recovery (Fig.2c).

Histochemical results

I. Total carbohydrates

In control rats and those treated with saffron, the total carbohydrates exist in the form of deeply stained reddish granules in the cytoplasm of hepatic cells and the nuclei gave a negative reaction (Fig. 3a). Hepatocytes of animals treated with SVP and examined after 3 and 6 weeks showed decrease in total carbohydrates and this decrease was marked after 6 weeks (Fig. 3b). Animals treated with SVP and saffron revealed an improvement in total carbohydrates contents of the hepatocytes when compared with the schedule treatment of SVP group after 6 weeks (Fig. 3c).

II. Total proteins

The protein materials in the hepatic cells of control rats were displayed in the cytoplasm in the form of small bluish irregular particles. The nuclear envelope, chromatin materials and nucleoli are positively stained (Fig. 4A). Examination of liver of animals treated with SVP showed that most of the cells appeared with cytoplasmic vacuolization and showed a reduction of their protein content (Fig. 4B). Animals treated with SVP followed by saffron and examined after 6 weeks revealed improvement of protein content and a large number of the hepatocytes contained considerable amounts of proteins while others showed moderate amount (Fig. 4C).

III. Deoxyribonucleic acid (DNA).

The DNA-containing particles (chromatin) appeared in the form of densely stained red particles distributed in the nucleoplasm and the peripheral rim of the nuclei (Fig. 5a). Hepatic cells examined 3 and 6 weeks after treatment with SVP revealed that most nuclei exhibited a weak Feulgen reaction of their chromatin granules indicating a reduced amount of DNA (Fig. 5b). Animals treated with SVP and saffron showed that most of the nuclei acquired normal amount of DNA-containing particles (Fig. 5c).

Biochemical results

Non-significant difference in serum ALT activity was recorded in rats treated with saffron extract in comparison with control group. Animals treated with SVP showed a significant increase in serum ALT activity after 6 weeks of treatment. On the other hand, animals treated with SVP and saffron revealed a significant decrease in ALT activity when compared with SVP group (Fig. 6a). Similarly, non-significant difference in serum AST activity was recorded in animals treated with saffron when compared with control group. Animals treated with SVP showed significant increase in serum AST activity while animals treated with SVP and saffron showed a significant decrease in AST activity when compared with SVP treated group (Fig. 6b).

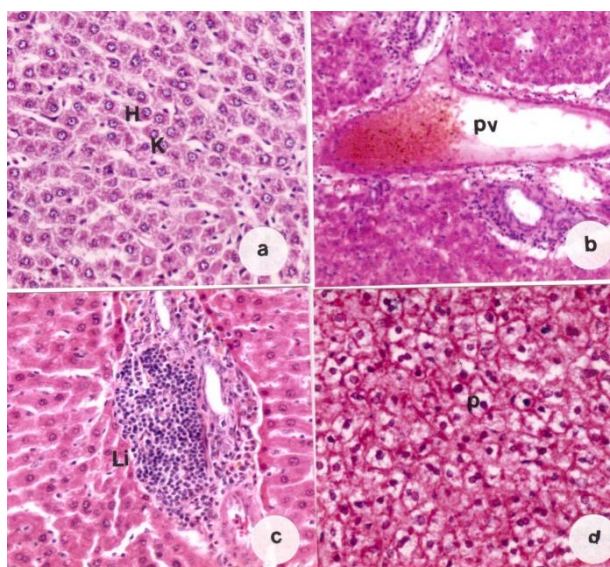


Fig. 1. a. liver section of a control rat showing hepatic lobule formed of cords of hepatocytes (H), Kupffer cells (K), and sinusoids (S), b. liver section of a rat treated with SVP for 3 weeks showing congested portal vein , c. liver section of a rat treated with SVP showing mass of leucocytic inflammatory cells (Li), d. liver section of a rat treated with SVP showing cytoplasmic vacuolation of the hepatocytes with pyknotic nuclei (P), (H&E, X 400).

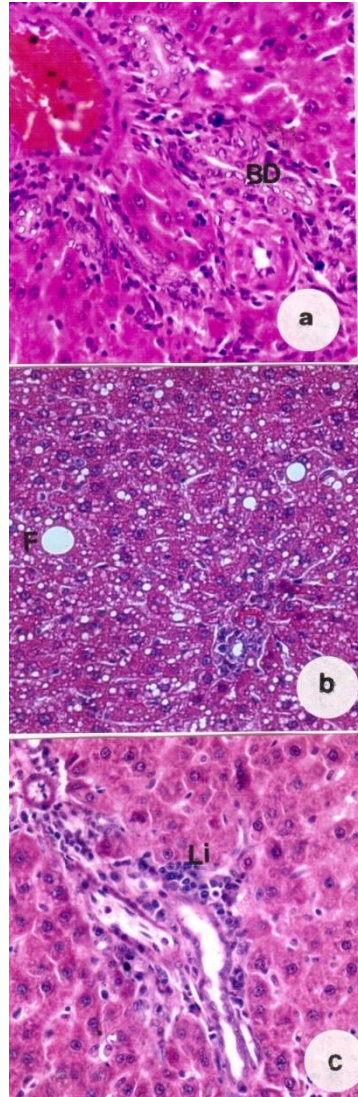


Fig. 2. a. liver section of a rat treated with SVP for 6 weeks showing bile duct proliferation (BD) , b. liver section of a rat treated with SVP showing Fatty degeneration (F), c. liver section of a rat treated with SVP and saffron showing nearly normal hepatocytes, and small area of inflammatory cells (Li), (H&E, X 400).

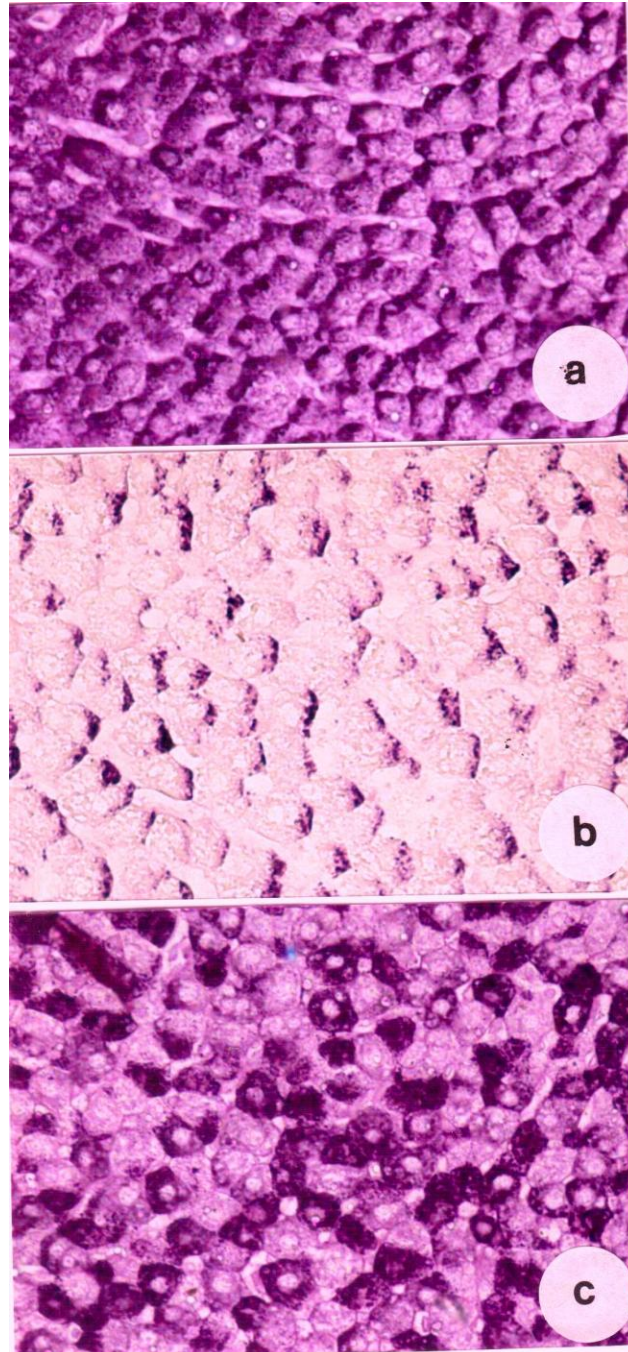


Fig. (3). a. liver section of a control rat showing PAS positive materials in the cytoplasm of the cells. The nuclei gave a negative reaction, b. Section of liver of a rat treated with SVP showing weak PAS reaction, c. A restoration of glycogen inclusions in hepatocytes of a rat given SVP and saffron (PAS X 400).

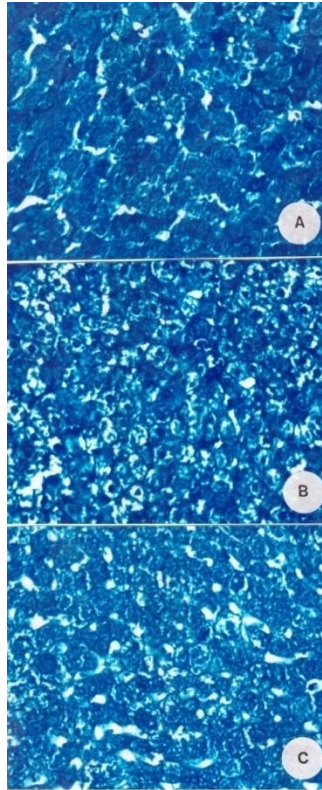


Fig. (4). A. Normal protein content in the hepatocytes of a control animal appears as dense bluish bodies in the cytoplasm. B. reduction of the protein content in the hepatic cells after treatment with SVP, C. Restoration of total protein content in most cells of a rat treated with SVP and saffron, (X 400)

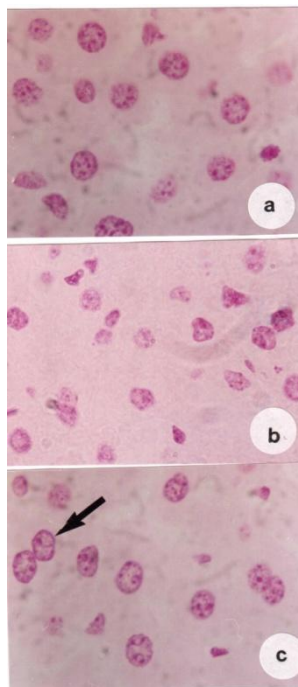


Fig. (5). a. Normal distribution of DNA-containing particles in the nuclei of hepatic cells of a control rat, b. diminution of DNA-containing particles in the nuclei of hepatic cells of an animal treated with SVP, c. liver section obtained from animal treated with SVP and saffron showing restoration of DNA stainability nuclei, binucleated cell (arrow)(X 1000).

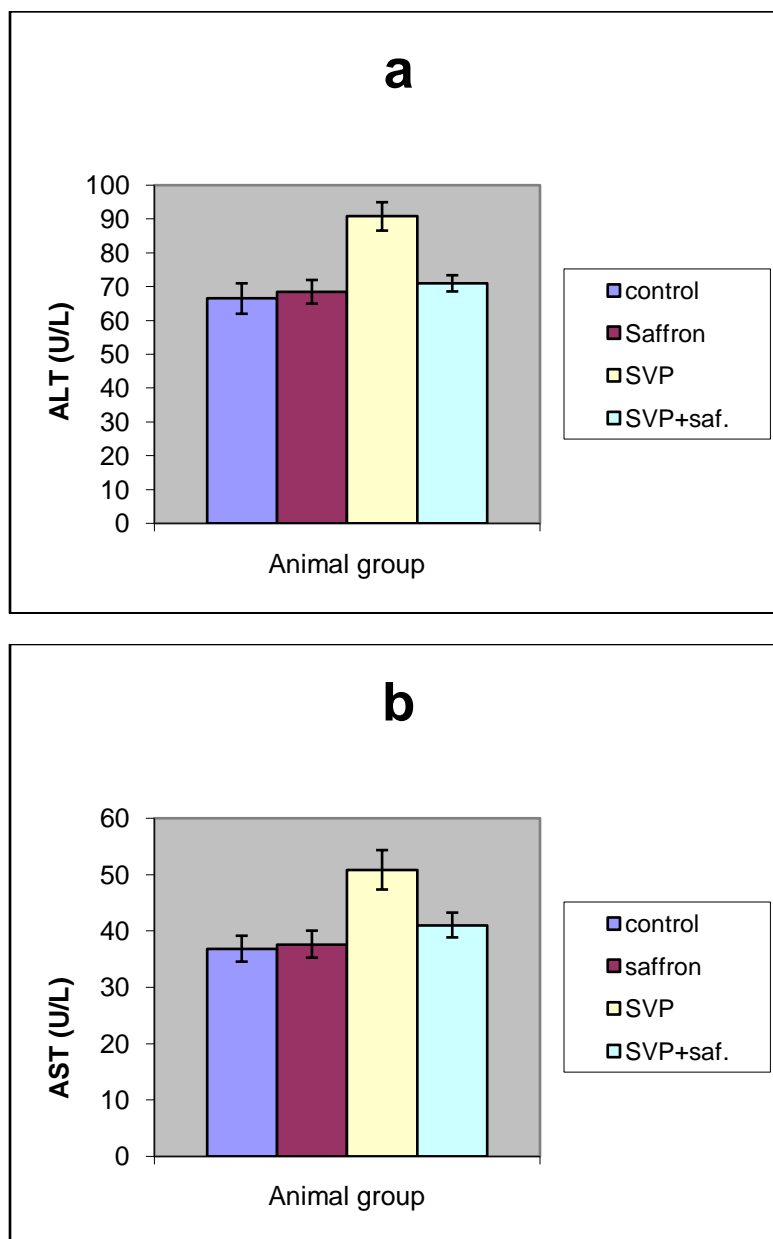


Fig.(6). Effect of different treatments on activity of (a) ALT and (b) AST.

Discussion

Results of the present study revealed that SVP induced hepatotoxicity in albino rats. These hepatotoxic effects are characterized by many histopathological alterations and elevation of serum level of ALT and SAT. Such increase in ALT and AST may be due to the damaged hepatocytes and bile duct proliferation observed in this work. These results confirmed previous findings of several investigators. Mathis et al.(1979) reported that microvesicular fatty change associated with necrosis appeared in liver of patients given valporate. Lewis et al. (1982) reported that administration of SVP to rats produced a dose dependent microvesicular hepatic steatosis. Stephens and Levy (1992) showed that depakene can cause liver damage and cause pancreatitis which occasionally progress to bleeding and

death. Treating mice with Valproic acid induces fatty degeneration of hepatocyte, swelling and increased number of kupfer cells. Prolonged time of administration produced inflammation of portal tract, necrosis and cirrhosis (Raza et al. 2000). Khan et al. (2005) reported that steatosis and necrosis of hepatocyte are the main histopathological changes in liver of albino rat induced by toxic dose of Valproic acid. Ibrahim (2012) reported that valproic acid induces toxic effects on liver tissue of mice which showed vacuolar degenerative changes, hypertrophied nucleus with fragmented chromatin, inflammatory cells aggregates and congested vasculature.

Treating rats with SVP induced a noticeable decrease in total carbohydrates, total proteins and DNA content in the hepatocytes. In agreement with these results, Ibrahim (2012) reported that VPA administration reduced total carbohydrates and proteins in hepatic tissue of mice. Kesterson et al. (1984) reported that PAS positive material was not observed in the hepatocytes of the rats treated with Valproic acid and its metabolites. Beger et al. (2009) showed that a single valproic acid treatment inhibits glycogen and RNA ribose turnover while disrupting glucose-derived cholesterol synthesis in liver of rats. They added that decreased RNA turnover may have far reaching and severe functional consequences affecting gene expression, protein synthesis and metabolism. Eickholt et al. (2005) reported that valproic acid inhibited glycogen synthase kinase-3B. In vivo studies have suggested that VPA may function to mimic the inhibition of GSK-3B by elevating the expression of B-catenin, a GSK-3B target, which is degraded upon phosphorylation (Phiel et al., 2001). Felisbino et al. (2011) reported that exposing HeLa cells to valproic acid caused DNA fragmentation and decrease of mitotic index.

Oxidative stress due to abnormal production of reactive oxygen species (ROS) is involved in the etiology of toxicities of many xenobiotics. Some studies have reported that oxidative stress plays a role in valporate-induced toxicity including hepatotoxicity. Vidya and Subramanian (2006) reported that SVP-treatment was found to increase levels of malondialdehyde and hydroperoxides and decreased levels of enzymatic (SOD, CAT and GPx) and non-enzymatic (GSH) antioxidants in rats. Raza et al. (2000) reported that malondialdehyde increased in liver of mice fed with sodium valproate for 21 days. The activities of superoxide dismutase, glutathione peroxidase, and glutathione reductase were insignificantly lower, whereas the malondialdehyde concentration was insignificantly higher in the erythrocytes of children with epilepsy treated with valporate (Sobaniec, 2006). Zhang et al. (2011) found that the levels of malondialdehyde in neutrophils of valporate-treated patients were higher while the activities of SOD and CAT were significantly lower than the control and untreated groups. Cotariu et al. (1990) reported that depletion of the antioxidant glutathione (GSH) has been proposed as one of the mechanisms leading to valproic acid-associated hepatotoxicity. Yukcel et al. (2001) have reported an increase in the lipid peroxidation and a decrease in glutathione peroxidase concentrations during valproate therapy as compared with those recorded in the pretreatment and control groups. Graf et al. (1998) added that the metabolism of valproate further leads to an increased free radical load of the body, which subsequently saturates and decreases the antioxidant enzymes. It was reported that SVP is metabolized to unsaturated toxic products in the body (Dreifuss et al. 1987, Rittle et al. 1987). These studies have shown that metabolites formed by omega oxidation pathway, 2-n-propyl-4-pentenoic acid and other delta dehydrogenation products may cause hepatotoxicity.

Saffron, in the present work, was found to improve the histological and histochemical alterations induced in the liver of rats by SVP. In accordance with this results, Anlin et al. (2000) reported that saffron extract has a curative effect against liver toxicity induced by alcohol and CCl₄ in rats. The serum level of ALT decreased significantly in saffron groups as compared with rats treated with alcohol and CCl₄. Treating mice exposed to AlCl₃ by saffron was found to improve the disrupted liver function enzymes (ALT, AST) and alleviated the increase of lipid peroxidation (Ali et al. 2010). Iranshahi et al. (2011) showed that aqueous and ethanolic extracts of saffron (stigma and petal) reduce the incidence of liver lesions induced by CCl₄ in mice. Mohajeri et al. (2011) reported that ethanolic extract of saffron ameliorated rifampin-induced histopathological and biochemical alterations in liver of rats.

Several studies reported the antioxidant activity of saffron and its extracts. Mohajeri and Douster. (2012) who found that ethanolic extract of saffron had the ability to reduce lipid peroxidation, and improve the antioxidant enzyme activities, superoxide dismutase, catalase, and GSH-related enzymes in liver of rats treated with cisplatin. It was reported that crocin has antioxidant properties and a large amount of it exists in saffron stigma (Hosseinzadeh et al. 2009). Iranshahi et al. (2011) proposed that the effectiveness of saffron stigmas in healing liver damages induced by CCl₄ is due to this glycosides. Giaccio (2004) reported that saffron component, crocetin, protects against AFB₁-induced hepatotoxicity and oxidation damage in rats with increase of glutathion-S-transferase. Saffron methanol extract was found to exhibit high antioxidant activity and high scavenging activity which is involved in

aging process, anti-inflammatory, anticancer and wound healing activity (Assimopoulou et al. 2005). Furthermore, administration of saffron resulted in modulation of lipid peroxidation, antioxidants and detoxification systems in genotoxins-induced oxidative stress in albino mice (Premkumar et al.2003). Treating mice with saffron improved learning and memory accompanied by reduced lipid peroxidation products, higher total brain antioxidant activity and reduced caspase-3 activity (Papandreou et al.2011). Our results suggested that saffron extract improved hepatotoxicity of SVP through inhibition of oxidative stress and enhancing the antioxidant defense system.

References

- Aktas,A., Nergiz,Y., , Akkus, M., Nasir,Y., (2010).** The effects of valproic acid on renal corpuscle of pregnant rats and protective role of folic acid and vitamin E. **African J. Biotechnology** 9(34) : 5605-5610.
- Ali, A., Shati, M. S. C., Saad, A. and Alamri, M. S. C. (2010) Role of saffron (*Crocus sativus* L.) and honey syrup on aluminum-induced hepatotoxicity, *Saudi Medical Journal*, 31 (10): 1106-1113.
- Anlin, M. A., Tiejong, W. U., Enyu, D. (2000) Prevention and treatment of saffron on experimental alcoholic and CCl₄ liver injury in Wistar rats. *Chinese J. Integrated Trad. Western Medicine on Liver Diseases*, 06-019.
- Assimopoulou,A.N., Sinakos, Z., Papageorgiou, V. P. (2005). Radical scavenging activity of *Crocus sativus* L. Extract and Its Bioactive Constituents, *Phytother. Res.* 19(11): 997-1000.
- Beger,R.D., Hansen,D.K., Schnackenberg, L.K., Cross,B.M., Javad J. Fatollahi F.Tracy,L.Z., Laszlo G. Boros,L.G. (2009). Single valproic acid treatment inhibits glycogen and RNA ribose turnover while disrupting glucose-derived cholesterol synthesis in liver as revealed by the [U-¹³C]-D-glucose tracer in mice. *Metabolomics* 5:336–345
- Cotariu, D., Evans,S., Zaidman ,J.L., Marcus, O. (1990). Early changes in hepatic redox homeostasis following treatment with a single dose of valproic acid. *Biochem. Pharmacol.* 40:589-593.
- Coyle,T.E., Bair, K.A., Mehdi,S.,Stein,C., Constance Stein, Wright, J.Vajpayee,N.(2005).Acute Leukemia Associated With Valproic Acid Treatment: A Novel Mechanism for Leukemogenesis?. *American Journal of Hematology* 78:256–260
- Dreifuss,F.E.,Santilli,N.,Langer,D.H.,Sweeney,K.P.,Moline,K.A.and Manander, K.B.(1987). Valproic acid hepatic fatalities: a retrospective review. *Neurology*,;37:379-385.
- Eickholt, B. J. Towers, G. J. Ryves, W. J. Eikel, D. Adley, K. Ylinen, L. M. J. Chadborn, N. H. Harwood, A. J. Nau, H. and Williams. R. S. B. (2005). Effects of valproic acid derivatives on inositol trisphosphate depletion, teratogenicity, glycogen synthase kinase-3 inhibition, and viral replication: A screening approach for new bipolar disorder drugs derived from the valproic acid core structure. *Mol Pharmacol* 67:1426–1433.
- Felisbino MB, Tamashiro WM, Mello ML. (2011). [Chromatin remodeling, cell proliferation and cell death in valproic acid-treated HeLa cells](#). *PLoS One*. 2011; 6(12):e29144. doi10.1371/journal.
- Gelder, M., Mayou, R., Geddes, J. (2006) *Psychiatry*. 3rd edition. Oxford: Oxford University Press.
- Giaccio, M.(2004). Crocetin from saffron: An Active Component of an Ancient Spice. *Critical Reviews in Food Sci. Nutr.* 44(3): 155-172.
- Gokee, S., Durmaz, Z., Coskun,E., Aydogan, A., Goglu,G., Mine; S, Semra., C. (2010). Valproic Acid-Associated Vanishing Bile Duct Syndrome *Journal of Child. Neurology.* 25 (7): 909
- Graf , W.D, Oleinik O,E, Glauser T.A, (1998). Altered antioxidant activities in children with a serious adverse experience related to valproic acid therapy. *Neuropediatrics* 29: 195–201.
- Hosseinzadeh H, Shamsaie F, Mehri , S (2009). Antioxidant activity of aqueous and ethanolic extracts of *Crocus sativus* L. stigma and its bioactive constituent, crocin and safranal. *Pharmacog Mag.* 2009;5:419-24.

Hosseinzadeh H, Karimi Gh, Niapoor M. (2004). Antidepressant effects of *Crocus sativus* stigma extracts and its constituents, crocin and safranal, in mice. *Acta Hort (ISHS)*, 650: 435-45.

Janneke J., Maria A. L., Dolk, H., Barisic, I., Garne, E., Morris, J.K., Lolkje T.W. (2010). Valproic Acid Monotherapy in Pregnancy and Major Congenital Malformations. *N Engl J Med* 362:2185-2193

Kesterson, W. J.; Granneman, G. R. and Joseph, M.M. (1984). The hepatotoxicity of valproic acid and its metabolites in rats. Toxicological, biochemical and histopathological studies. *The American Association for the Study of Liver Diseases*, 6: 1143-1152.

Khan, S. K.; Shakoor, K. A.; Jan, M. A.; Khattak, A. M. and Shah, S. H. (2005): study of histopathological changes in the liver of albino rats, induced by toxic dose of Valproic acid. *Gomal journal of medical sciences*, (3):15-18

Kiernan, J. A. (1981). *Histological and Histochemical Methods, Theory and Practice*. Pergamon Press. New York, USA.

Ibrahim, M. A. (2012). Evaluation of Hepatotoxicity of Valproic acid in albino mice, Histological and Histochemical studies. *Life Sci J*;9(4):153-159

Iranshahi, M., Khoshangosht, M., Mohammadkhani, Z., Karimi, G. (2011). Protective effects of aqueous and ethanolic extracts of saffron stigma and petal on liver toxicity induced by carbon tetrachloride in mice. *Pharmacologyonline* 1: 203-212

Lewis, J.H, Zimmerman, H. J, Garrett, C.T, Rosenberg, E.V. (1982). Valproate-induced hepatic steatogenesis in rats. *Hepatology* ;2:870-3

Mathis, R.K, Lindhal, J A, Freese D.K, Sharp, H.L.(1979). Valproic acid and hepatocyte failure in children. *Paediatr Res* , 13:527.

Mohajeri, D., Doustar, Y. (2012). Protective effect of ethanolic extract of *Crocus sativus* L. (Saffron) stigma against Cisplatin induced hepatotoxicity in rats. *Med Sci J Islamic Azad Univ*. 21 (4) :251-261

Mohajeri D, Doustar Y, Rezaei A, Mesgari-Abbasi M. (2011). Hepatoprotective effect of ethanolic extract of *Crocus sativus* L. (Saffron) stigma in comparison with silymarin against rifampin induced hepatotoxicity in rats. *Zahedan J. Res. Med. Sci.*, 12 (5) :53-59

Nair, S. C., Pannikar, B. and Panikkar K. R. (1991) Antitumor activity of saffron (*Crocus sativus*), *Cancer Letters*, vol. 57(2):109-114.

Nair SC, Kurumboor SK, Hasegawa JH. (1995) Saffron chemoprevention in biology and medicine: a review. *Cancer Biother*, 10: 257-64.

Ornoy A. (2006). Neuroteratogens in man: An overview with special emphasis on the teratogenicity of antiepileptic drugs in pregnancy. *Reprod. Toxicol.* 22, 214–226.

Papandreou, M.A., Tsachaki, M., Efthimiopoulos, S., Cordopatis, P., Lamari, F., Margaritis, M. (2011). Memory enhancing effects of saffron in aged mice are correlated with antioxidant protection. *Behavioural Brain Res.* 219 : 197–204

Pearse, A. G. E. (1972). *Histochemistry, Theoretical and Applied*, 3rd ed., vol. 2. Churchill Livingstone. London.

Phiel CJ, Zhang F, Huang EY, Guenther MG, Lazar MA, and Klein PS (2001) Histone deacetylase is a direct target of valproic acid, a potent anticonvulsant, mood stabilizer and teratogen. *J Biol Chem* **276**: 36734 –36741.

Premkumar K, Abraham SK, Santhiya ST, Ramesh A. (2003). Protective effects of saffron (*Crocus sativus* Linn.) on genotoxins-induced oxidative stress in Swiss albino mice. *Phytother Res*;17:614–7.

Raza, M.A.; Bekairi, O.A.; and Quershi, S.M. (2000). pathomorphological changes in mouse liver and kidney during prolonged valproate administration Int.J.Tissue React., 22 (1): 15-21.

Reitman, S. and Frankel, S. (1957). A colorimetric method for the determination of serum glutamic oxalacetic and glutamic pyruvic transaminases. Am J Clin Pathol, 28(1): 56-63.

Rios JL, Recio MC, Ginger RM, Manz S. (1996). An update review of saffron and its active constituents. *Phytother Res* 10: 189-193.

Rittle, A.E., Rettewmeier, A.W., Howard, W.N. and Baillie, T.A. (1987). Cytochrome P450 catalysed formation of VPA, a toxic metabolite of valproic acid. *Science*, 235:890-893.

Sobaniec, W. (2006). Evaluation of the Influence of Antiepileptic Therapy on Antioxidant Enzyme Activity and Lipid Peroxidation in Erythrocytes of Children With Epilepsy. *J. Child Neurology*, 21:558-562

Stephens, R., Levy, H., 1992. Valproate hepatotoxicity syndrome: hypothesis of pathogenesis. *Pharm. Weekbl. Scient.* 14:118-121.

Vidya, M. and Subramanian, S. (2006). Effects of micro-ketoglutarate on antioxidants and lipid peroxidation products in rats treated with sodium valproate. *J. Applied Biomedicine* 6:141-146.

Yukcel .A, Cengiz M., Seven M., Ulutin T.(2001). Changes in the antioxidant system in epileptic children receiving antiepileptic drugs: Two year prospective studies. *J Child Neurol*, 16: 603-6.

Zhang YJ, Zhang M, Wang XC, Yu YH, Jin PJ, Wang Y. (2011). Effects of sodium valproate on neutrophils' oxidative metabolism and oxidant status in children with idiopathic epilepsy. *Zhonghua Er Ke Za Zhi*. 49(10):776-81.